ENDOSCOPY AND BARIUM IN HYPERCONTRACTILE DISORDERS

Nicola de Bortoli,
University of Pisa

Clinical presentation of esophageal hypercontractile motility disorders

- CHEST PAIN
- DYSPHAGIA
- REGURGITATION
- HEARTBURN

ROLE OF ENDOSCOPY IN UPPER GI SYMPTOMS

TABLE 2. Indications for endoscopy in patients with GERD

GERD symptoms that are persistent or progressive despite appropriate medical therapy
Dysphagia or odynophagia
Involuntary weight loss $>5\%$
Evidence of GI bleeding or anemia
Finding of a mass, stricture, or ulcer on imaging studies
Screening for Barrett's esophagus in selected patients (as clinically indicated)
Persistent vomiting (7-10 days)
Evaluation of patients before or with recurrent symptoms after endoscopic or surgical antireflux procedures
Placement of wireless pH monitoring

Esophageal Disorders

Peter J. Kahrilas, MD[1] and André J.P.M. Smout, MD, PhD[2]

Am J Gastroenterol 2010; 105:747–756; doi:10.1038/ajg.2010.65

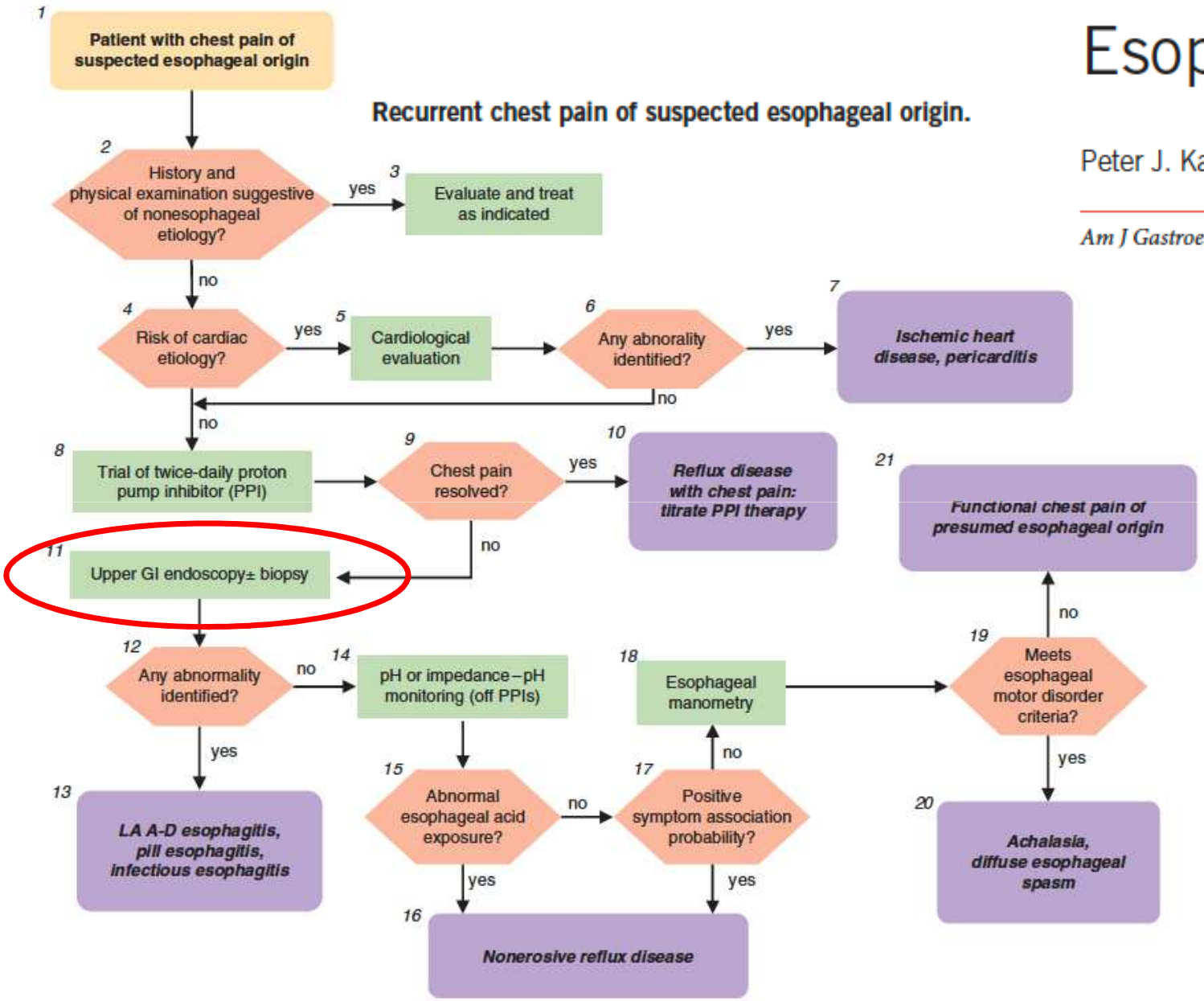

DYSPHAGIA

Esophageal Disorders

Peter J. Kahrilas, MD[1] and André J.P.M. Smout, MD, PhD[2]

Am J Gastroenterol 2010; 105:747–756; doi:10.1038/ajg.2010.65

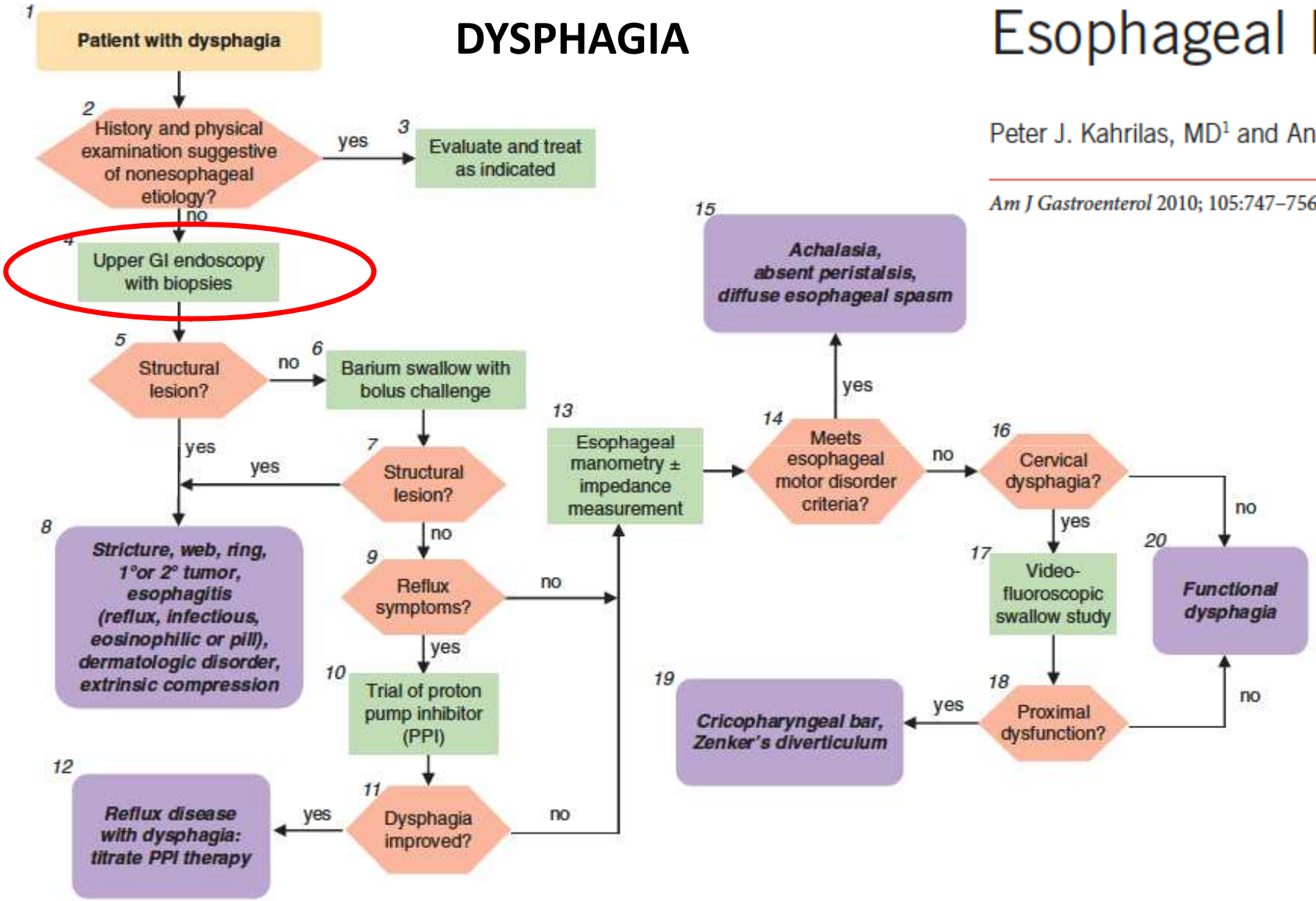

WHAT YOU CAN FIND DURING UPPER ENDOSCOPY

- Hiatal Hernia (sliding o paraesophageal)
- Erosions (GERD)
- Rings
- Furrows
- Stenosis (peptic or neoplastic)
- Food Impaction
- Diverticulum

WHAT YOU CAN FIOND DURING UPPER ENDOSCOPY

SCHATZKI RING

- 4% of endoscopy
- Thin membrane at the squamocolumnar junction
- Congenital or acquired
- Frequently asymptomastic
- Sometime is considered to be GERD related

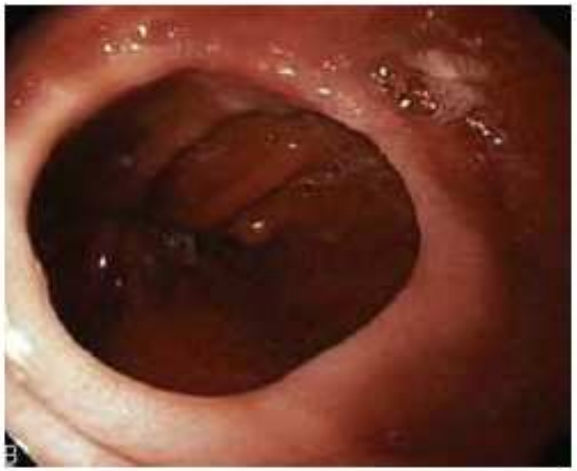

WHAT YOU CAN FIND DURING UPPER ENDOSCOPY

No specific endoscopic abnormalities is revealed during upper endoscopy in Hypercontractile motility disorders

S. Roiman and P.J. Kahrilas. Gastroenterol Clin North Am. 2013

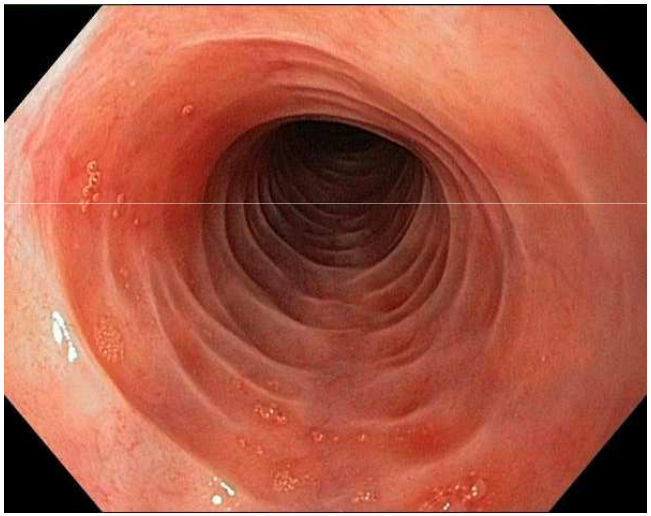

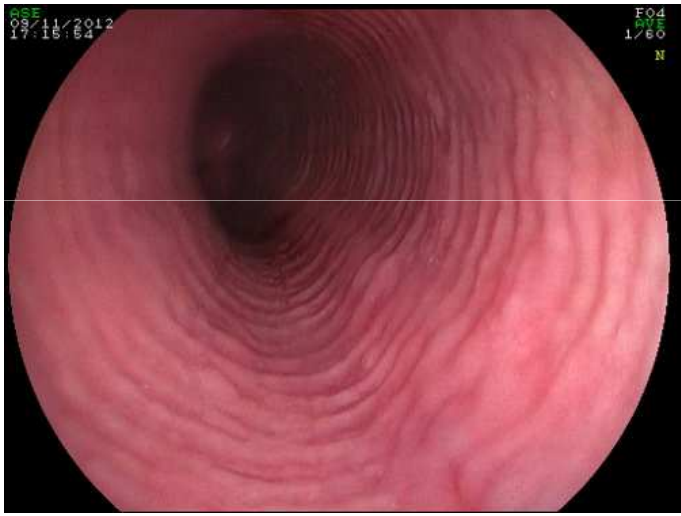

BIOPSIES…BIOPSIES…..BIOPSIES… FOR EXCLUDING EOE.

Major features

- **Fixed rings** (also referred to as concentric rings, corrugated oesophagus, corrugated rings, ringed oesophagus, trachealisation)
  - Grade 0: none
  - Grade 1: mild (subtle circumferential ridges)
  - Grade 2: moderate (distinct rings that do not impair passage of a standard diagnostic adult endoscope (outer diameter 8–9.5 mm))
  - Grade 3: severe (distinct rings that do not permit passage of a diagnostic endoscope)
- **Exudates** (also referred to as white spots, plaques)
  - Grade 0: none
  - Grade 1: mild (lesions involving <10% of the oesophageal surface area)
  - Grade 2: severe (lesions involving >10% of the oesophageal surface area)
- **Furrows** (also referred to as vertical lines, longitudinal furrows)
  - Grade 0: absent
  - Grade 1: present
- **Oedema** (also referred to as decreased vascular markings, mucosal pallor)
  - Grade 0: absent (distinct vascularity present)
  - Grade 1: loss of clarity or absence of vascular markings
- **Stricture**
  - Grade 0: absent
  - Grade 1: present

Minor features

- **Crepe paper oesophagus** (mucosal fragility or laceration upon passage of diagnostic endoscope but not after oesophageal dilation)
  - Grade 0: absent
  - Grade 1: present

Hirano I et al. Gut 2013;62:489–495

mild

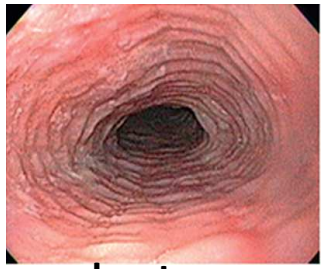
moderate

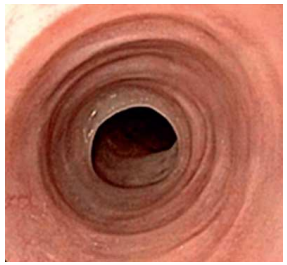
severe

FIXED RING

mild

severe

WHITE EXUDATES

FURROWS

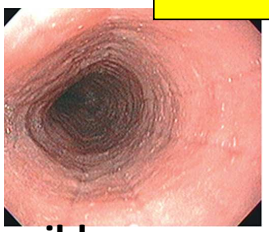
mild

severe

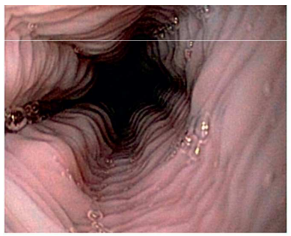
Time 0

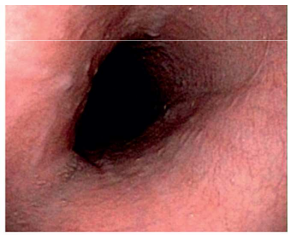
Time 1 (with insufflation)

OEDEMA

mild

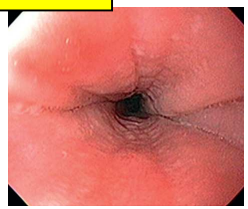
severe

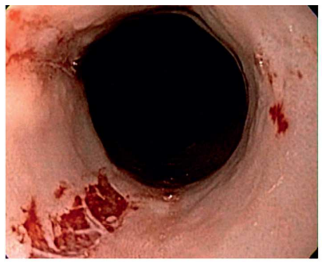

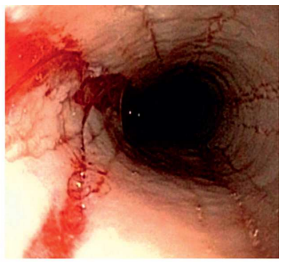

CREPE-PAPER ESOPHAGUS

Histology in EoE

Biopsy Guidelines

- Take 2 biopsies from upper, middle and lower esophagus (Inflammatory changes in patients with EoE might be focal and might not be present in all biopsy specimens from a single patient)
- Take biopsies from stomach and duodenum
- Ask the pathologist to
  - Count the peak concentration (per hpf) obtained from the most densely populated hpf
  - Identify superficial layering of eosinophils
  - Identify micro abscesses
  - Assess other markers of inflammation: extracellular eosinophil granules, basal cell hyperplasia, dilated intercellular spaces, papillary elongation, subepithelial
  - lamina propria fibrosis, and increases in numbers of other cell types

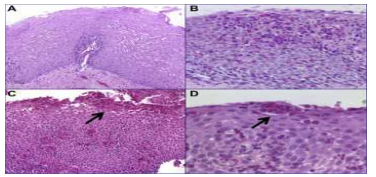

> 15 Eosinophils (Eos) per high power field (peak)

A case of Jackhammer esophagus caused by eosinophilic esophagitis in which per-oral endoscopic myotomy resulted in symptom improvement

Shinwa Tanaka[1,2] · Takashi Toyonaga[2] · Fumiaki Kawara[1] · Daisuke Watanabe[1] · Namiko Hoshi[1] · Hirohumi Abe[1] · Ryusuke Ariyoshi[1] · Yoshiko Ohara[1] · Tsukasa Ishida[1] · Toshitatsu Takao[1] · Yoshinori Morita[1] · Eiji Umegaki[1]

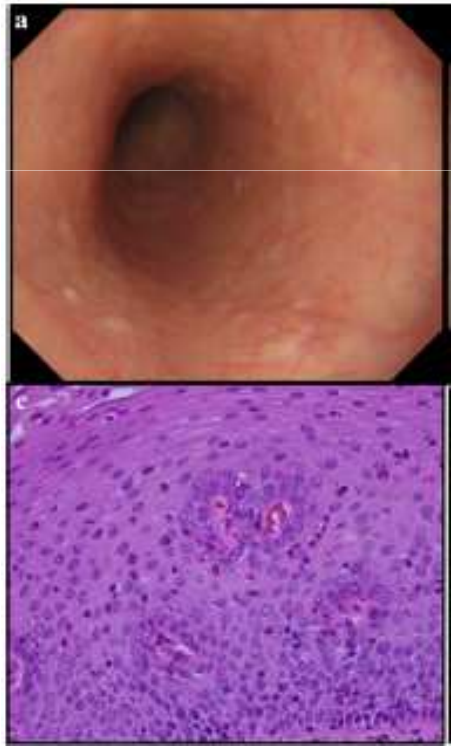

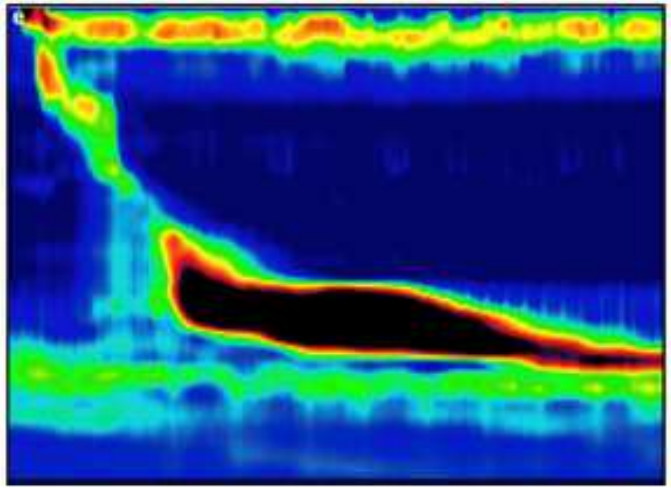

Nutcracker and jackhammer esophagus treatment: a three-case survey, including two novel cases of eosinophilic infiltration into the muscularis propria

Hiroki Sato[1], Manabu Takeuchi[1], Kazuya Takahashi[1], Yuichi Sato[1], Satoru Hashimoto[1], Kenichi Mizuno[1], Kenji Suzuki[1], Masaaki Kobayashi[1], Terasu Honma[2], Haruhiro Inoue[3], Shuji Terai[1]

Endoscopy 2015; 47: 855–857

Fig. 1 Endoscopic views showing: **a** an edematous esophageal wall and compressed lumen, even with an adequate air supply; **b**,**c** in a reversed view, the esophagus twining around the endoscope.

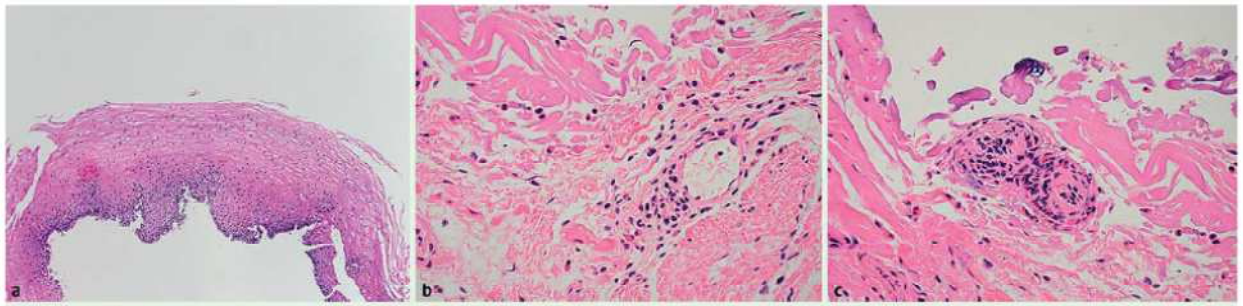

Fig. 4 Histologic views of a full-thickness muscle biopsy showing: **a** a lack of characteristic findings in the epithelium; **b**,**c** eosinophilic infiltration in the perivascular and perimysial area, which indicated eosinophilic esophagitis that was localized to the proper muscle layer and was therefore considered to be "eosinophilic esophageal myositis" (EoEM).

Eosinophils in the mucosa (>15/HPF)

↓

Systemic Prednisone

↓

Eosinophilic myositis
in deep esophageal biopsies.

Clinics and Practice 2015; volume 5:784

EPIPHRENIC ESOPHAGEAL DIVERICULUM

Large epiphrenic diverticula: a rare case presentation

Ajay H. Bhandarwar, Pravin N. Tungenwar, Yogesh M. Sawakare, Amol Nanasaheb Wagh, Chintan Babubhai Patel, Saurabh S. Gandhi

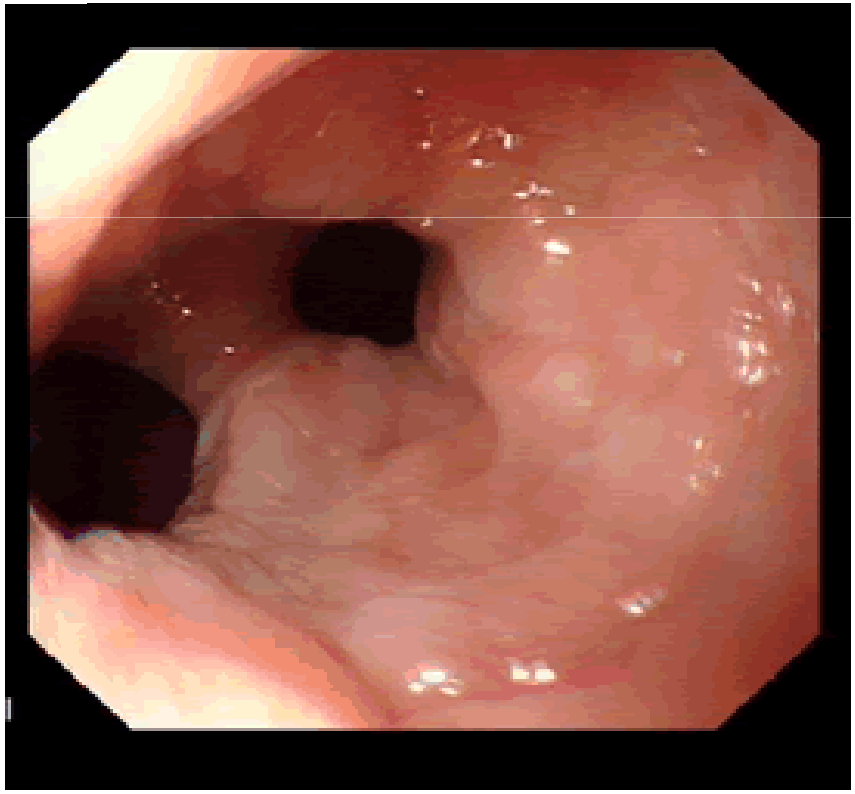

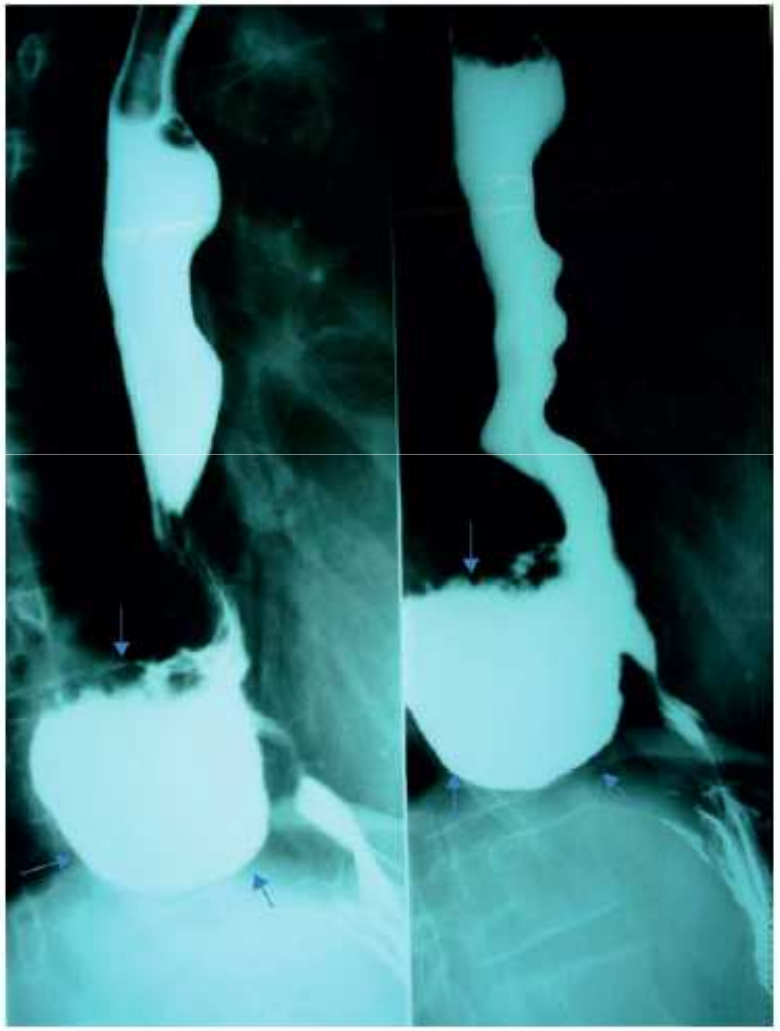

Midesophageal Pulsion Diverticulum Resulting From Hypercontractile (Jackhammer) Esophagus

Onkar V. Khullar, MD, Sagar R. Shroff, MD, Sonali S. Sakaria, MD, and Seth D. Force, MD

Section of General Thoracic Surgery and Division of Digestive Diseases, Emory University School of Medicine, Atlanta, Georgia

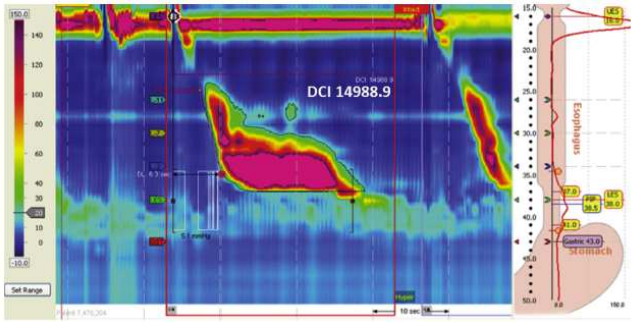

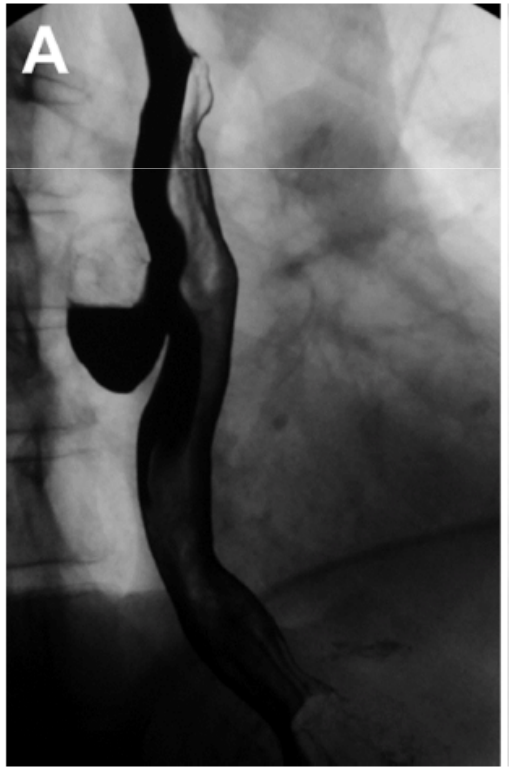

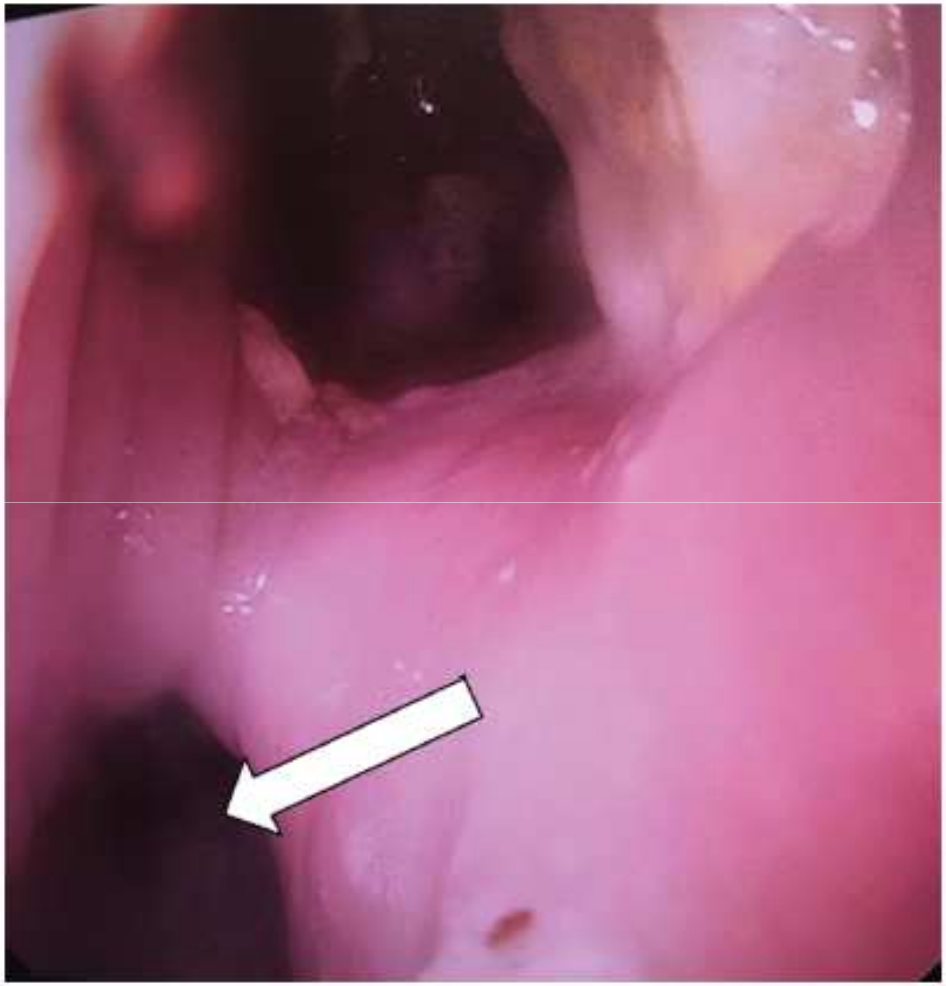

Fig 1. Esophagoscopy revealed a large midesophageal diverticulum (arrow).

Jackhammer Esophagus Accompanied by Esophageal Intramural Pseudodiverticulosis

Kazuya Takahashi, Satoshi Ikarashi, Junji Yokoyama and Shuji Terai

Intern Med 2018; 57: 1051-1052

Endoscopy revealed multiple small holes, a whitish mucosa, and a relatively narrow lumen (Picture 1, black arrow). Esophagography with barium swallow revealed multiple flask-shaped projections throughout the cervical and upper thoracic esophagus. We therefore diagnosed the patient with esophageal intramural pseudodiverticulosis (EIPD).

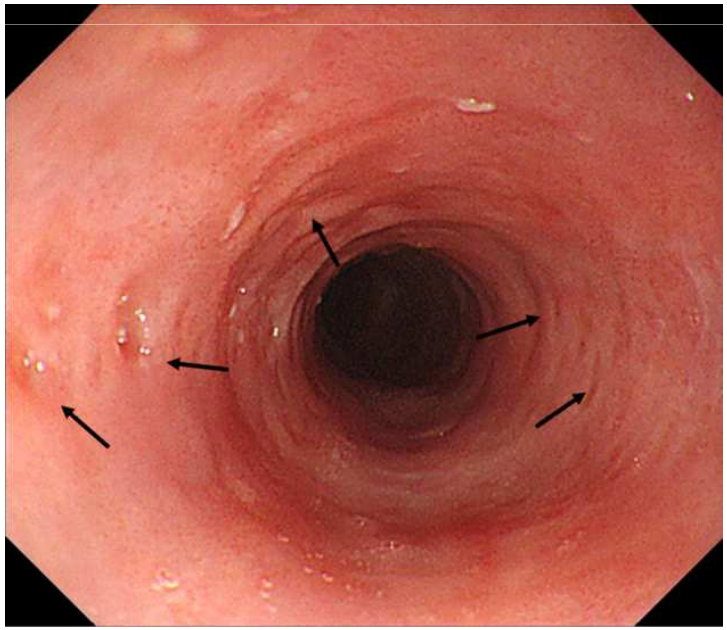

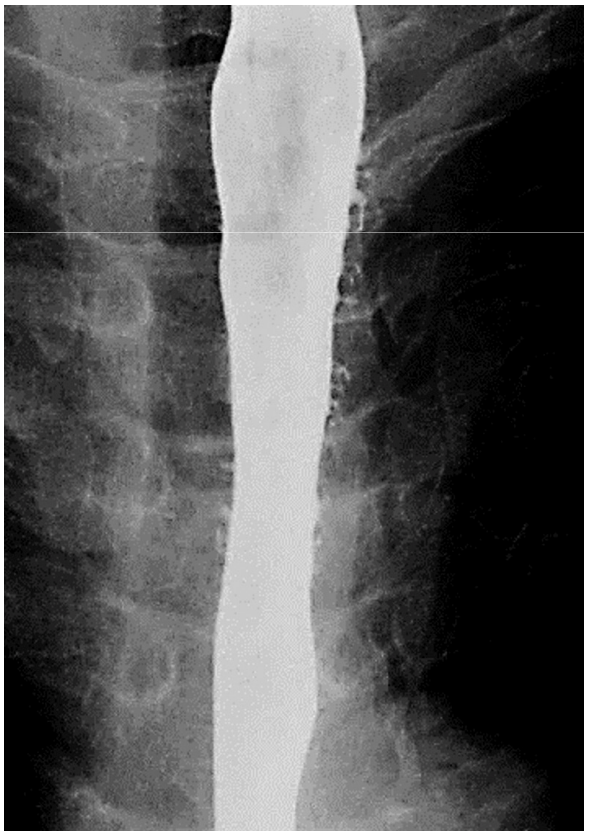

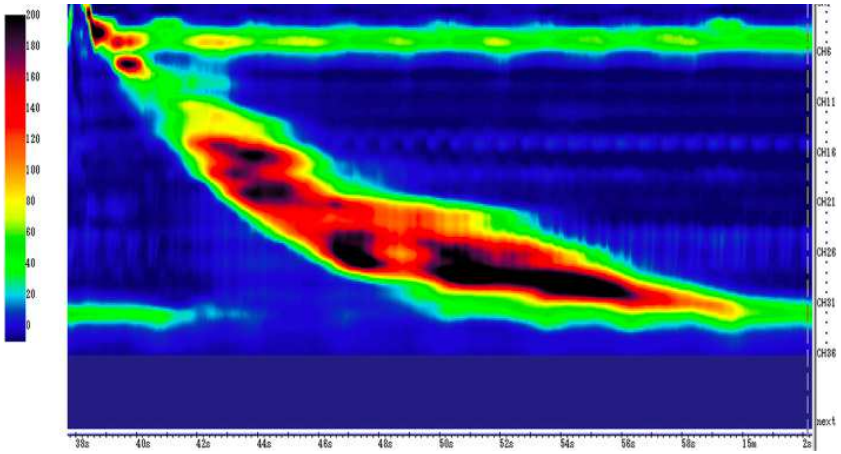

Barium X Ray

Barium Esophagograms in GERD

- Barium esophagram should be performed in all patients prior to anti-reflux surgery
- Useful information
  - Esophageal length
  - Presence and size of hiatus hernia, diverticulum

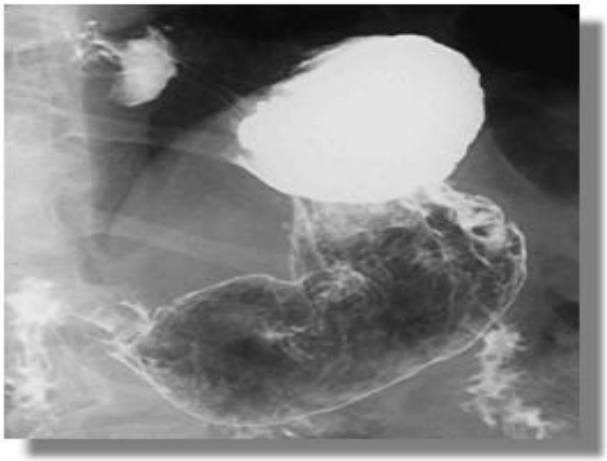

Fuchs KH et al. Surg Endosc. 2014; 28(6):1753-73
Jobe BA et al. J Am Coll Surg 2013;217:586

Barium Esophagograms in Achalasia

RADIOLOGIC FEATURES OF ACHALASIA (60% vs. HRM):

- Stasis of ingested foods/liquids in the distal esophagus
- Esophageal atony
- Esophageal dilation (megaesophagus)
- Lack or reduced of LES opening («bird-beak» appearance)
- Delayed passage within distal esophagus
- Delayed esophageal emptying
- Widening of the proximal esophagus
- absence of intragastric air bubble

WHAT YOU CAN FIND DURING BARIUM X-RAY
…related to hypercontratile esophageal disorders

Stenosis (organic – functional)
Cork-Screw
Epifrenic diverticulum
OIPD (Oesophageal Intraluminal PseudoDiverticulosis)

OIPD

(Oesophageal Intraluminal PseudoDiverticulosis)

-Rare

-Multiple , tiny flask-shaped outpouchings

-90% have associated strictures

-Mainly in the upper third of the esophagus

Epiphrenic diverticulum

-Occur less frequently than ZD , comprising less than 10% of all oesophageal diverticula

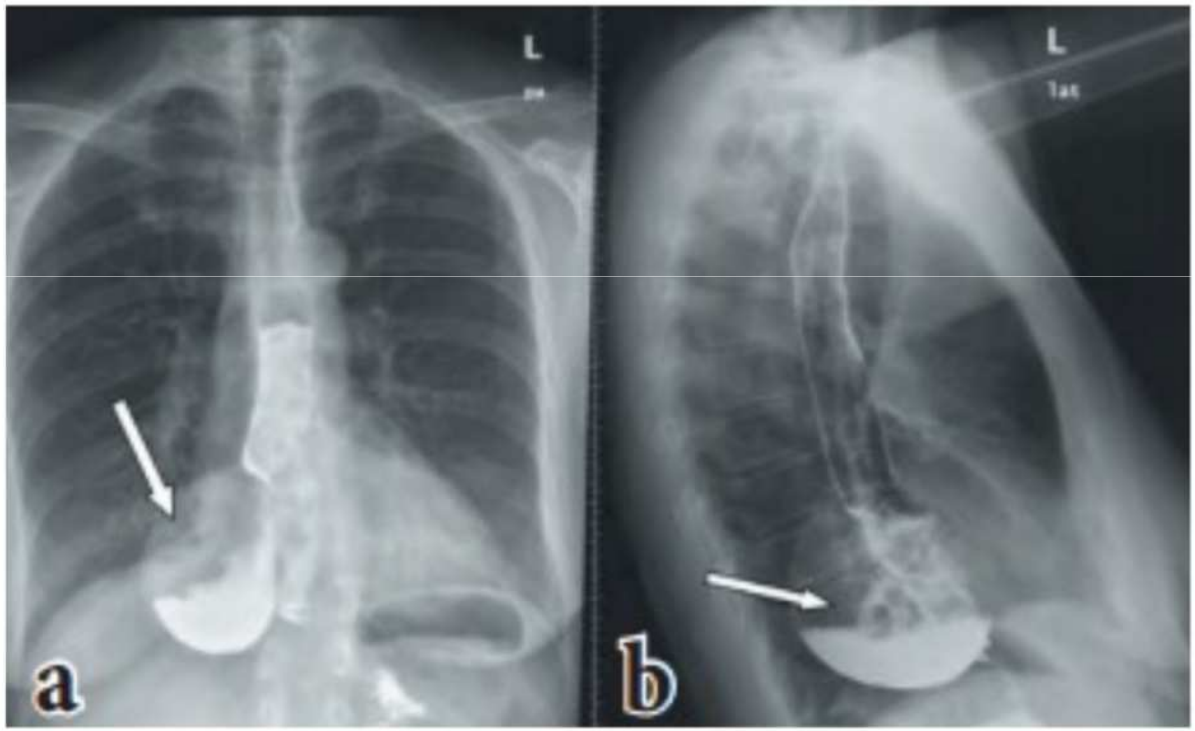

Barium swallow shows large epiphrenic diverticulum (arrow)

CORCK-SCREW

- Barium swallow shows diffuse esophageal spasm with simultaneous and uncoordinated contractions
- This characteristic “corkscrew” appearance is not specific for DES or other hypercontractile esophageal disorders.
- HRM should be performed

Richter JE. Lancet 2001; 358:823–8.

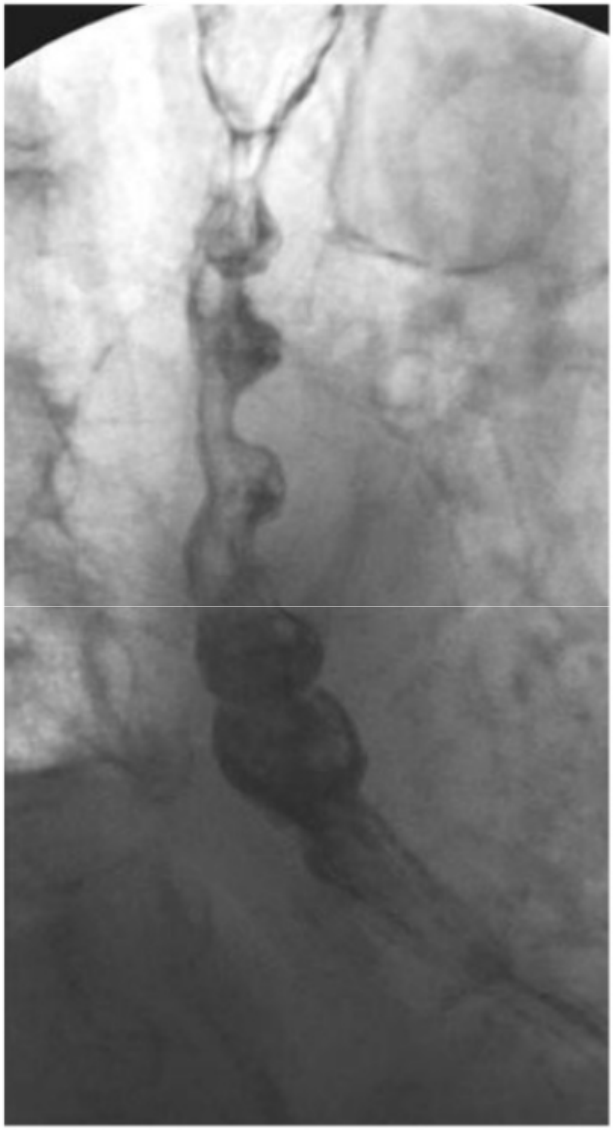

Gender, medication use and other factors associated with esophageal motility disorders in non-obstructive dysphagia

Afrin Kamal[1], Sampurna Shakya[1], Rocio Lopez[2], Prashanthi N. Thota[1,*]

Gastroenterology Report, 6(3), 2018, 177–183

NO EVIDENCES FOR ENDOSCOPY AND RADIOLOGY

Table 2. Esophagogastroduodenoscopy, high-resolution esophageal manometry (HREM) and pH findings of patients with non-obstructive dysphagia

	Normal manometry (N = 76)	Achalasia/EGJ outflow obstruction (N = 21)	Hypermotility disorders (N = 13)	Hypomotility disorders (N = 45)	P-value
Endoscopic findings					
Any abnormality	22 (28.9)	6 (28.6)	6 (46.2)	20 (44.4)	0.25[a]
Esophagitis	8 (10.5)	2 (9.5)	2 (15.4)	11 (24.4)	0.18[a]
Barrett's esophagus	1 (1.3)	0 (0.0)	0 (0.0)	1 (2.2)	0.99[b]
Schatzki ring	11 (14.5)	1 (4.8)	2 (15.4)	6 (13.3)	0.69[a]
Dilated esophageal lumen	3 (3.9)	6(28.6)[d]	2(15.4)	5(11.1)	0.01[a]
Ringed appearance	1 (1.3)	0 (0.0)	0 (0.0)	0 (0.0)	0.99[b]
Esophageal ulcers	0 (0.0)	0 (0.0)	0 (0.0)	1 (2.2)	0.51[b]
Esophageal diverticulum	1 (1.3)	0 (0.0)	0 (0.0)	0 (0.0)	0.99[b]
Hiatal hernia	27 (35.5)	2 (9.5)	4 (30.8)	18 (40.9)	0.08[a]
Esophageal histological findings					0.06[b]
Normal	16 (57.1)	3 (50.0)	–	2 (22.2)[d]	
Reflux changes	11 (39.3)	1 (16.7)	–	6 (66.6)	
Barrett's esophagus	1 (3.6)	2 (33.3)	–	1 (11.1)	
Findings on HREM					
Basal UES pressure, mmHg	55.0 [39.4, 72.7]	50.9 [39.6, 74.6]	55.8 [19.1, 65.5]	57.4 [36.7, 93.5]	0.60[c]
Basal LES pressure, mmHg	25.4 [15.7, 38.8]	42.7 [35.3, 54.6][d]	26.1 [15.8, 40.7]	14.0 [7.3, 24.5][d, e]	<0.001[c]
Residual LES pressure, mmHg	3.0 [1.5, 6.1]	20.8 [15.1, 23.7][d]	7.0 [4.7, 8.4][d, e]	1.9 [0.3, 4.5][e, f]	<0.001[c]
Distal contractile integral	1721.6 [1141.1, 2446.2]	1172.6 [675.7, 3737.4]	3782.1 [1303.5, 8624.4]	441.7 [317.4, 690.4][d, e, f]	<0.001[c]
Contractile front velocity	3.3 [2.7, 4.3]	8.0 [3.1, 21.5]	3.1 [2.4, 5.2]	3.0 [2.4, 4.2]	0.09[c]
Average intrabolus pressure	11.7 [7.7, 14.6]	24.0 [18.5, 30.2][d]	13.5 [12.4, 15.5][e]	10.1 [7.5, 14.2][e]	<0.001[c]
Distal latency	6.7 [5.8, 7.7]	5.6 [3.8, 6.5][d]	5.3 [4.7, 7.0]	7.1 [6.3, 7.9][e]	0.001[c]
pH Testing	N = 16	N = 5	N = 4	N = 10	
Total % of time pH ≤4	2.8 [0.25, 9.0]	3.3 [1.00, 14.2]	8.2 [0.30, 17.7]	2.9 [1.6, 12.2]	0.78[c]
Abnormal total reflux	6 (37.5)	2 (40.0)	2 (50.0)	4 (36.4)	0.99[b]
Upright % time spent in reflux	2.2 [0.25, 9.6]	5.1 [1.5, 14.2]	5.6 [0.40, 13.6]	3.5 [1.00, 16.5]	0.71[c]
Abnormal upright reflux	6 (37.5)	2 (40.0)	2 (50.0)	4 (36.4)	0.99[b]
Supine time spent in reflux (%)	0.00 [0.00, 4.7]	0.30 [0.20, 14.2]	7.9 [0.15, 25.0]	1.6 [0.00, 2.5]	0.48[c]
Abnormal supine reflux	5 (31.3)	2 (40.0)	2 (50.0)	2 (18.2)	0.67[b]
DeMeester score	10.4 [1.5, 25.9]	11.8 [4.6, 58.2]	29.2 [2.1, 68.6]	12.0 [7.2, 35.0]	0.74[c]
Abnormal DeMeester score	8 (50.0)	2 (40.0)	2 (50.0)	4 (36.4)	0.96[b]

What is the clinical significance of esophagogastric junction outflow obstruction? evaluation of 60 patients at a tertiary referral center

F. C. Okeke[1] | S. Raja[2] | K. L. Lynch[3] | S. Dhalla[4] | M. Nandwani[5] | E. M. Stein[4] | B. Chander Roland[4] | M. A. Khashab[4] | P. Saxena[4,6] | V. Kumbhari[4] | N. K. Ahuja[4] | J. O. Clarke[5]

60 patients with EGJ-OO

BARIUM X-RAY

Forty patients with EGJOO underwent a barium X-Ray.

- 11 (28%) normal
- 29 (72%) recorded abnormalities.
  - hiatal hernia (20 pts)
  - spasm or significant dysmotility (17 pts)
  - EGJ narrowing (10 pts)
  - Schatzki's ring (5 pts)
  - EGJ mass (1 pts).

ENDOSCOPY

Forty-one patients with EGJOO underwent upper endoscopy

- 19 (46%) had normal study.
- 26 (63%) endoscopic abnormalities
  - hiatal hernia (13, 32%).
  - Schatzki's ring (6, 15%)
  - esophagitis (3, 7%),
  - candidiasis (3, 7%)
  - EGJ mass (1).

		Response		
Intervention	n	Sustained	Transient	None
Dilation (<= 20 mm)	9	1 (12%)	4 (44%)	4 (44%)
Botulinum injection	6	1 (17%)	3 (50%)	2 (33%)
Per oral endoscopic myotomy	3	3 (100%)		
Medications*	7			7 (100%)
Proton pump inhibitors	8	2 (25%)		

*Calcium channel blockers, nitroglycerin, muscle relaxants, sildenafil.

NO FINDING DURING ENDOSCOPY OR X-RAY WERE ASSOCIATED TO SYMPTOMATIC IMPROVEMENT OR RECURRENCE

Neurogastroenterol Motil. 2017;29:e13061.

The clinical significance of esophagogastric junction outflow obstruction and hypercontractile esophagus in high resolution esophageal manometry

D. Schupack | D. A. Katzka | D. M. Geno | K. Ravi

56 EGJ outflow-obstruction (EGJOO)

40 Hypercontractile Esophagus (HE)

33 Controls

	EGJOO (n=56)	HE (n=40)	Control (n=33)
Esophageal structure and function			
Obstruction on esophagram	3/36 (8%)	3/25 (12%)	2/15 (13%)
Obstruction on EGD	5/40 (13%)	3/30 (10%)	2/28 (7%)
Erosive esophagitis or Barrett's on EGD	3/40 (8%)	2/30 (7%)	3/28 (11%)

NO differences between groups

NO RADIOLOGIC OR ENDOSCOPIC FINDING WERE ASSOCIATED WITH OUTCOME

Neurogastroenterology & Motility. 2017;e13105.

Phenotypes and clinical context of hypercontractility in high resolution esophageal pressure topography (EPT)

Am J Gastroenterol. 2012 January ; 107(1): 37–45.

Sabine Roman, **John E Pandolfino**, **Joan Chen**, **Lubomyr Boris**, **Daniel Luger**, and **Peter J Kahrilas**
Department of Medicine, The Feinberg School of Medicine, Northwestern University, Chicago, IL

Clinical characteristics of patients with hypercontractility.

	Multipeaked synchronized with respiration (n=20)	Multipeaked not synchronized with respiration (n=16)	Not multipeaked (n=8)
Mean age (range) yrs	54 (28–69)	57 (28–78)	68 (48–82)
Gender (M/F)	7/13	7/9	5/3
Dysphagia, n (%)	13 (65%)	12 (75%)	7 (88%)
Reflux, n (%)	6 (30%)	5 (31%)	2 (25%)
Chest pain, n (%)	3 (15%)	1 (6%)	1 (13%)
Endoscopic findings	n=18	n=15	n=8
Normal	10	5	4
Hiatal hernia	3	3	1
Eosinophilic inflammation	0	2	1
Reflux esophagitis	2	1	1
Other (Schatzki ring, etc)	3	4	1
Barium swallow	n=6	n=7	n=5
Slightly delayed transit	0	1	0
Delay transit of barium tablet	1	1	1
Follow-up obtained	n=16	n=12	n=5
Good treatment response	11¶	7≠	4*

NO differences between groups

CONCLUSION

All patients with dysphagia should undergo upper endoscopy in order to rule out malignancy.

Endoscopy is first line approach when red signs are present.

Few finding are indicative of hypercontractile disorders of the esophagus.

Barium X-Ray is an adjunctive test after endoscopy and before doing surgery or endoscopic treatment.

Barium X-Ray is indicated to better define size and localization of esophageal diverticula.

Endoscopic or radiological findings did not show having any prognostic value.